

SARCOCYSTOSIS IN CATTLE AND SHEEP AT PRAGUE ABATTOIR

Ž. ČERNÁ and V. MERHAUTOVÁ

Faculty of Sciences, Charles University, Prague

Abstract. A total of 288 animal oesophagi, including 154 from cattle and 134 from sheep of various age, were examined for the presence of sarcosporidians at Prague abattoir. The material from cattle was positive in 129 cases (84%) and all the three species of sarcosporidians hitherto described from cattle were identified: *Sarcocystis cruzi*, *S. hirsuta* and *S. hominis*. Among the sheep, 110 animals (82%) were infected. The macroscopic species *S. tenella* was found in 23 cases. The remaining positive findings were cystozoites and microscopic cysts of *Sarcocystis* including *S. ovicanis* (in 19 cases).

With the increasing knowledge of the morphology and life-cycles of sarcosporidians, heteroxenous coccidians, which are often pathogenic, attention has been focused on their specific occurrence and distribution in animals of economic importance.

Three species of *Sarcocystis* have been reported from cattle: *Sarcocystis cruzi* (syn. *S. bovicanis*), *S. hirsuta* (syn. *S. bovivelfis*) and *S. hominis* (syn. *S. bovi-hominis*). They differ in the definitive hosts and morphology of developmental stages, as it is shown in Table 1. The table includes the data from the following papers: Fayer and Johnson (1973, 1974), Fayer (1974), Johnson et al. (1975), Gestrich et al. (1975 a, b), Heydorn et al. (1975), Tadros and Laarman (1976), Frelief et al. (1977), Boch et al. (1978).

Of the *Sarcocystis* infecting sheep only two species have been described in detail: *Sarcocystis tenella* (syn. *S. ovifelis*) and *S. ovicanis*. However, cyst stages not belonging to any of these species have already been recorded (see, e.g., Boch et al. 1979). Table 2 shows data on the life-cycle and pathogeny of the two mentioned species, using the following papers: Rommel et al. (1972), Gestrich et al. (1974), Heydorn et al. (1975), Munday et al. (1975), Heydorn and Gestrich (1976), Mehlhorn et al. (1976), Leek et al. (1977).

The results obtained during the examination of the material from Prague abattoir are presented in this paper. The material was kindly supplied by Dr. F. Štícha of the Veterinary Service at Prague abattoir.

MATERIAL AND METHODS

The material was obtained from cattle and sheep of various age slaughtered at the abattoir in Prague. Muscles of oesophagi were examined either on the same day or on 3rd day after slaughtering at the latest. The material which could not be examined on the day of slaughtering was kept at the ice-box temperature (4°C) until further processing.

The muscles of oesophagi were cut to about 10 cm long pieces and mixed in 50 ml of saline. After filtration through gauze and centrifugation, the presence of free cystozoites, cysts or fragments of cysts of sarcosporidians in the sediment was investigated.

RESULTS

Examinations of cattle

Sarcosporidians were found in 129 (84 %) of the 154 oesophagi of cattle examined. Microscopical examinations at the magnification of 100 \times revealed occasional infection (one or no cystozoites in the viewing field) in 97 cases, regular infection (2 and more cystozoites) in 28 cases and massive infection (more than 10 cystozoites) in 4 cases.

The infection was identified most frequently on the basis of the presence of cystozoites, but microscopic cysts and fragments of cysts enabling specific determination of sarcosporidians were also encountered (Plate I, Figs. 1,2). The cysts were absent or unidentified in 86 cases. In 43 cases, the cysts were identified as *S. cruzi* (26 \times), *S. hirsuta* (20 \times) and *S. hominis* (7 \times). *S. cruzi* and *S. hirsuta* occurred as a mixed infection in some cases.

Table 1. *Sarcocystis* from cattle

Species	<i>S. cruzi</i> (<i>S. bovicanis</i>)	<i>S. hirsuta</i> (<i>S. bovifelis</i>)	<i>S. hominis</i> (<i>S. bovihominis</i>)
Definitive host	dog	cat	man
Sporocysts eliminated by definitive host	13—22 \times 9—15 μ m	11—14 \times 7—9 μ m	13—17 \times 8—11 μ m
Prepatent period	9—10 days	7—9 days	7—9 days
Cyst structures in cattle	thin-walled, microscopic	thick-walled, finger-like elevations of wall (6.7 \times 1.5 μ m)	thick-walled, finger-like elevations of wall (5 \times 0.7 μ m)
Pathogenicity	pathogenic	non-pathogenic or mildly pathogenic	non-pathogenic or mildly pathogenic

Table 2. *Sarcocystis* from sheep

Species	<i>S. tenella</i> (<i>S. ovifelis</i>)	<i>S. ovis</i>
Definitive host	cat	dog
Sporocysts expelled by definitive host	11—14 \times 8—9 μ m	13—16 \times 8—11 μ m
Prepatent period	11—14 days	8—9 days
Cyst structures in sheep	macroscopic, wall of cauliflower-like structure	microscopic, wall smooth, formed by short, finger-like, 2—3.5 μ m high processes
Pathogenicity	apparently little pathogenic	pathogenic

The highest number of positive cases were determined on the basis of the presence of cystozoites. The mixed material contained also young cyst structures, the wall of which did not yet correspond to the wall characteristics of mature cysts of some of the three species described from cattle (see Table 1). Nevertheless, cysts of all hitherto described sarcosporidian species occurring in cattle were identified in 43 oesophagi.

Examinations of sheep

Sarcosporidians were found in 110 (82 %) of the 134 sheep oesophagi examined. The cystozoites were found in 87 cases: occasional infection 78×, regular infection 8× and massive infection 1×. Macroscopical cysts ("macrocyts") of *S. tenella* were found in 23 sheep examined, i.e. in 21 % of positive sheep. In the remaining 87 (79 %) positive cases, the material contained cystozoites and microscopic cysts ("microcyts"). Microcyts and cystozoites were found in 21 cases. Except two cases, the microcyts conformed to the description of muscle cysts of *S. ovis* (Plate II, Figs. 1 A—C).

DISCUSSION AND CONCLUSIONS

Already the preliminary serological examinations of cattle in three uniform agricultural cooperatives in southern Bohemia performed by indirect immunofluorescence technique revealed that the sarcocystosis is widely spread in cattle in this country (Černá and Červa 1979). Antibodies were detected in 59 (69 %) of 85 examined animals. Koudela et al. (1972), who examined trichinoscopically a set of 95 heads, detected sarcocystosis only in 17 animals, but they noted that in histological examinations the positivity was higher (in 19 of 30 animals). A high infestation of cattle with sarcosporidians has recently been reported from F.R.G. and Austria. Boch et al. (1978) found among 1020 heads of cattle 57.9 % of positive animals if examined by a trichinoscope and as much as 99.7 % if the method of muscle trypsinization was used. Kepka and Österreicher (1979) reported 94.3 % of positive cases among 2307 animals examined and Hinaidy et al. (1979), who examined by a trichinoscope 511 animals, recorded 87 % of positive cases. The first results of examination of mixed oesophagus muscles from Prague abattoir indicate that the situation is similar in our country. In our material, the positivity to sarcosporidians was 84 % and as determined on the basis of the cysts recovered, all the three species of *Sarcocystis* hitherto described from cattle were involved. *S. cruzi*, which is pathogenic for cattle, occurred in more than one half of cases in which the cysts were found. The results show that fatal sarcocystosis, as described by Schmitz and Wolf (1977) from the U.S.A., can also occur in Czechoslovakia.

Examinations of sheep revealed a high percentage of *Sarcocystis* infection. Of the total number of 134 sheep oesophagi examined, 110 (82 %) contained these parasites. Macroscopic cysts of *S. tenella* occurred in 21 % of sheep examined, whereas in the remaining cases cystozoites and microscopic cysts were detected. We assume that most of the cases were infected with *S. ovis*, the microscopic cysts of which were identified in 19 cases. Our results correspond to those of Boch et al. (1979) obtained by trypsinization of sheep muscles. They examined for sarcocystosis 500 animals in F. R. G. 85.4 % of positive cases were detected by trypsinization and only 33.2 % by a trichinoscope. Macroscopic cysts of *S. tenella* were found by these authors in 2.6 % of cases only. Our findings of pathogenic species *S. ovis* in the material from Prague abattoir indicate that under unfavourable conditions this parasite could cause a spontaneous fatal infection in lambs as it was demonstrated experimentally by Leek et al. (1977) in the USA.

It may be concluded that the examinations of cattle and sheep from Prague abattoir support our assumption that sarcocystosis caused by pathogenic species can be involved in the disorders and deaths of young specimens of these economically important animals.

Ж. Черна и В. Мергаутова

Резюме. На присутствие саркоспоридий обследовали 288 пищеводов животных разного возраста (154 из крупного рогатого скота и 134 из овец) в пражской скотобойне. Материал из крупного рогатого скота оказался положительным в 129 случаях (84 %) и были обнаружены все до сих пор описанные у крупного рогатого скота виды саркоспоридий: *Sarcocystis cruzi*, *S. hirsuta* и *S. hominis*. Среди овец обнаружено 110 (82 %) положительных животных. Макроскопический вид *S. tenella* встречался в 23 случаях. Другие положительные находки были цистозонты и микроскопические цисты *Sarcocystis*, включая *S. ovis* (в 19 случаях).

REFERENCES

- BOCH J., BIERSCHECK A., ERBER M., WEILAND G., *Sarcocystis* und *Toxoplasma*-Infektionen bei Schlachtschafen in Bayern. Berl. Münch. tierärztl. Wschr. 92: 137—141, 1979.
- , LAUPHEIMER K. E., ERBER M., Die Sarcosporidienarten bei Schlachtrindern in Süddeutschland. Berl. Münch. tierärztl. Wschr. 91: 426—431, 1978.
- ČERNÁ Ž., ČERVA L., Serological positivity for sarcocystosis in intermediate hosts of man-infecting species of the genus *Sarcocystis*. Paper read at the conference "Epidemiology and prevention of human parasitoses caused by worms". Košice 3—4 May 1979. (In Czech.)
- FAYER R., Development of *Sarcocystis fusiformis* in the small intestine of the dog. J. Parasitol. 60: 660—665, 1974.
- , JOHNSON A. J., Development of *Sarcocystis fusiformis* in calves infected with sporocysts from dogs. J. Parasitol. 59: 1135 to 1137, 1973.
- , —, *Sarcocystis fusiformis*: development of cysts in calves infected with sporocysts from dogs. Proc. Helm. Soc. Wash. 41: 105—108, 1974.
- FRELIER P., MAYHEW I. G., FAYER R., LUNDE M. N., *Sarcocystis*: a clinical outbreak in dairy calves. Science 195: 1341 to 1342, 1977.
- GESTRICH R., HEYDORN A. O., BAYSU N., Beiträge zum Lebenszyklus der Sarkosporidien. VI. Untersuchungen zur Artendifferenzierung bei *Sarcocystis fusiformis* und *Sarcocystis tenella*. Berl. Münch. tierärztl. Wschr. 88: 191—197, 1975a.
- , —, MEHLHORN H., Licht- und elektronenmikroskopische Untersuchungen an Cysten von *Sarcocystis fusiformis* in der Muskulatur von Kälbern nach experimenteller Infektion mit Oocysten und Sporocysten der grossen Form von *I. bigemina* der Katze. Zbl. Bakt. I. Abt. Orig. A. 233: 261—276, 1975b.
- , SCHMITT M., HEYDORN A. O., Pathogenität von *Sarcocystis tenella*-Sporozysten aus den Fäzes von Hunden für Lämmer. Berl. Münch. tierärztl. Wschr. 87: 362—363, 1974.
- HEYDORN A. O., GESTRICH R., Beiträge zum Lebenszyklus der Sarkosporidien. VII. Entwicklungsstadien von *Sarcocystis ovis* im Schaf. Berl. Münch. tierärztl. Wschr. 89: 1—5, 1976.
- , —, MEHLHORN H., ROMMEL M., Proposal for a new nomenclature of the Sarcosporidia. Z. Parasitenk. 48: 73—82, 1975.
- HINAIDY H. K., BURGU A., SUPPERER R., KALLAB K., Sarkosporidienbefall des Rindes in Österreich. Wien. tierärztl. Wschr. 66: 181—183, 1979.
- JOHNSON A. J., HILDEBRANDT P. K., FAYER R., Experimentally induced *Sarcocystis* infection in calves: pathology. Am. J. Vet. Res. 36: 995—999, 1975.
- KEPKA O., ÖSTERREICHER H. D., Zur Häufigkeit von Sarkosporidien in Rindern der Steiermark. Wien. tierärztl. Wschr. 66: 184—185, 1979.
- KOUDELA K., TREFNÝ D., BLÁŽEK K., FREUDL A., Sarcocystosis in fattened cattle. Vet. Med. (Praha) 17: 407—411, 1972. (In Czech.)
- LEEK R. G., FAYER R., JOHNSON A. J., Sheep experimentally infected with *Sarcocystis* from dogs. I. Disease in young lambs. J. Parasitol. 63: 642—650, 1977.
- MEHLHORN H., HARTLEY W. J., HEYDORN A. O., A comparative ultrastructural study of the cyst wall of 13 *Sarcocystis* species. Protistologica 12: 451—467, 1976.
- MUNDAY B. L., BARKER I. K., RICKARD M. D., The developmental cycle of a species of *Sarcocystis* occurring in dogs and sheep, with observations on pathogenicity in the intermediate host. Z. Parasitenk. 46: 111 to 123, 1975.
- ROMMEL M., HEYDORN A. O., GRUBER F.,

Beiträge zum Lebenszyklus der Sarkosporidien. I. Die Sporozyste von *S. tenella* in den Fäzes der Katze. Berl. Münch. tierärztl. Wschr. 85: 101–105, 1972.

SCHMITZ J. A., WOLF W. W., Spontaneous fatal sarcocystosis in a calf. Vet. Pathol. 14: 527–531, 1977.

Received 11 July 1980.


TADROS W., LAARMAN J. J., *Sarcocystis* and related coccidian parasites: a brief general review, together with a discussion on some biological aspects of their life cycles and a new proposal for their classification. Acta Leidensia 44: 1–107, 1976.

Ž. Č., Přírodovědecká fakulta KU, Viničná ul. 7, 128 44 Praha 2, ČSSR

FOLIA PARASITOLOGICA (PRAHA) 28: 129–130, 1981.

Docent Dr. Techn. Ing. Jan Rozsypal is 85

In the past thirty years the Czechoslovak parasitology has flourished into a spreading system of scientific subdisciplines. Dr. Techn. Ing. Jan Rozsypal, Associate Professor at the School of Agriculture in Brno, bearer of the decoration for "Distinction in Labour" has devoted his entire successful professional career to the disciplines concerned with plant parasitology. He was born in Vyškov on 11 May 1896 in the family of a progressive-minded teacher.



He graduated from the Brno School of Agriculture in 1921 and immediately began to work in agricultural research, becoming a co-worker of the outstanding specialist in plant protection, Prof. Dr. Techn. Ing. Eduard Baudyš. Dr. Rozsypal followed in the footsteps of his teacher and soon became a leading parasitologist in his field. Between the parasite and its host plant he always saw a dialectic whole, a duel of contradictory elements, in which defeated is always the component of the two lacking good conditions for life. Therefore Dr. Rozsypal put

a great emphasis on correct agrotechnical procedures and on the hygiene of the fields. His treatise "Sugar Beet pest *Bothynoderes punctiventris* Germ. and its natural enemies" (Sborník Vysoké školy zemědělské Brno, ser. agronom. 16: 1 to 101), already a classic, may serve as an example of this attitude. This work reflects his keen interest in entomophagous parasitic fungi, the subject of his many other mycologic-parasitological studies, such as "*Macrosiphum pisi* Kalt. and *Entomophthora aphidis* Hoffm" (Práce MPS 4: 1–20); "A few notes on *Lecanium coryli* L. infesting ash-trees and fungi parasitic on it" (Ochrana rostlin 13: 153–176); "Fungi parasitic on *Heterodera schachtii* Schmidt in Moravian soils" (Věst. ČAZ 10: 403–422); "Mycotic infection of *Calliphora vomitoria* L." (Zool. Listy 6: 12–20); "A contribution to entomophagous fungi" (Čs. parasitologie 5: 169–177) etc.

Dr. Rozsypal enriched the international collection of the cultures of entomophagous fungi in Holland with several hitherto unknown taxons and himself described two new species: *Entomophthora zabri* sp.n. from a serious grain pest *Zabrus tenebrioides* Goeze and *Metarrhizium flavoviride* sp.n. from the much-feared poppy pest *Ceutorhynchus maculaalba*.

In his research Dr. Rozsypal also focused attention on bacterial and viral infections. The results of his studies are treated in his papers "On viroses of *Papaver somniferum* L." (Čs. biologie 5: 218–226, 6: 438–440); "Organisms destroying insects" (Sborník Klubu Přír. Brno 26: 91–98); "On infectious diseases of greenhouse and hotbed plants" (In: Kurs praktické hygieny skleníků a pařenišť — A course of practical hygiene of green-houses and hotbeds) etc.

A significant section in Dr. Rozsypal's scientific research in the field of parasitology are his studies in phytohelminthology. His complex view of the unity of the pest and its host plant yielded progressive and in many respects advanced

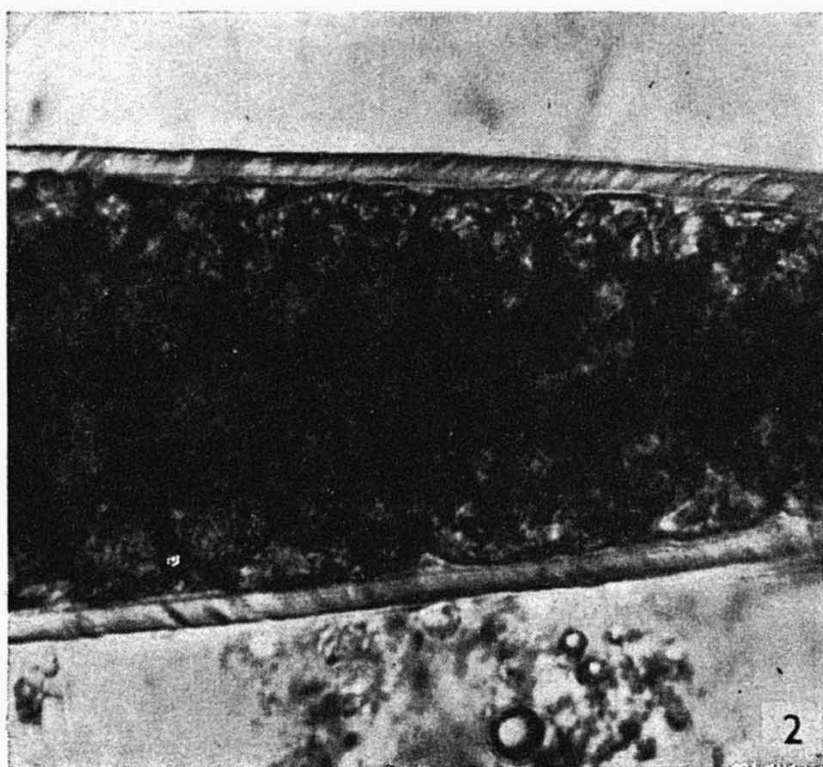
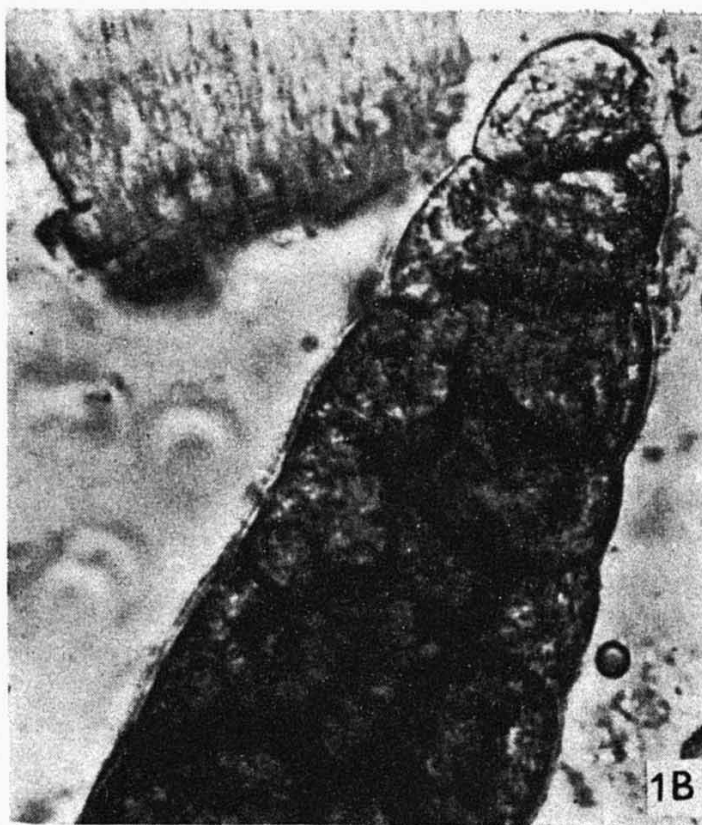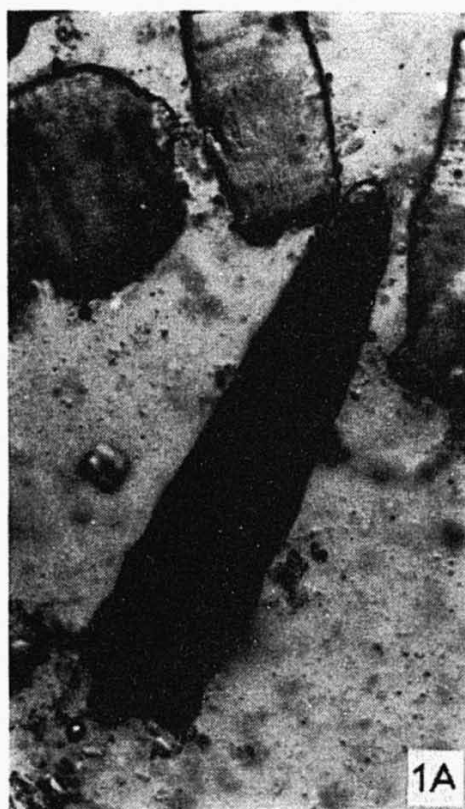


Fig. 1. *Sarcocystis cruzi* from cattle. A — fragment of cyst (in the middle) between fragments of muscle fibres in material from mixed oesophagus muscles. Fresh. ($\times 150$). B — detail of the same cyst structure; thin wall of cyst well visible. ($\times 900$).

Fig. 2. *Sarcocystis hominis* from cattle. A part of thick-walled cyst. The wall is formed from finger-like processes appearing like a not very distinct radial striation in this species. ($\times 900$). The Figures of cysts were made on the basis of native preparations so that the structure of their wall were visible.

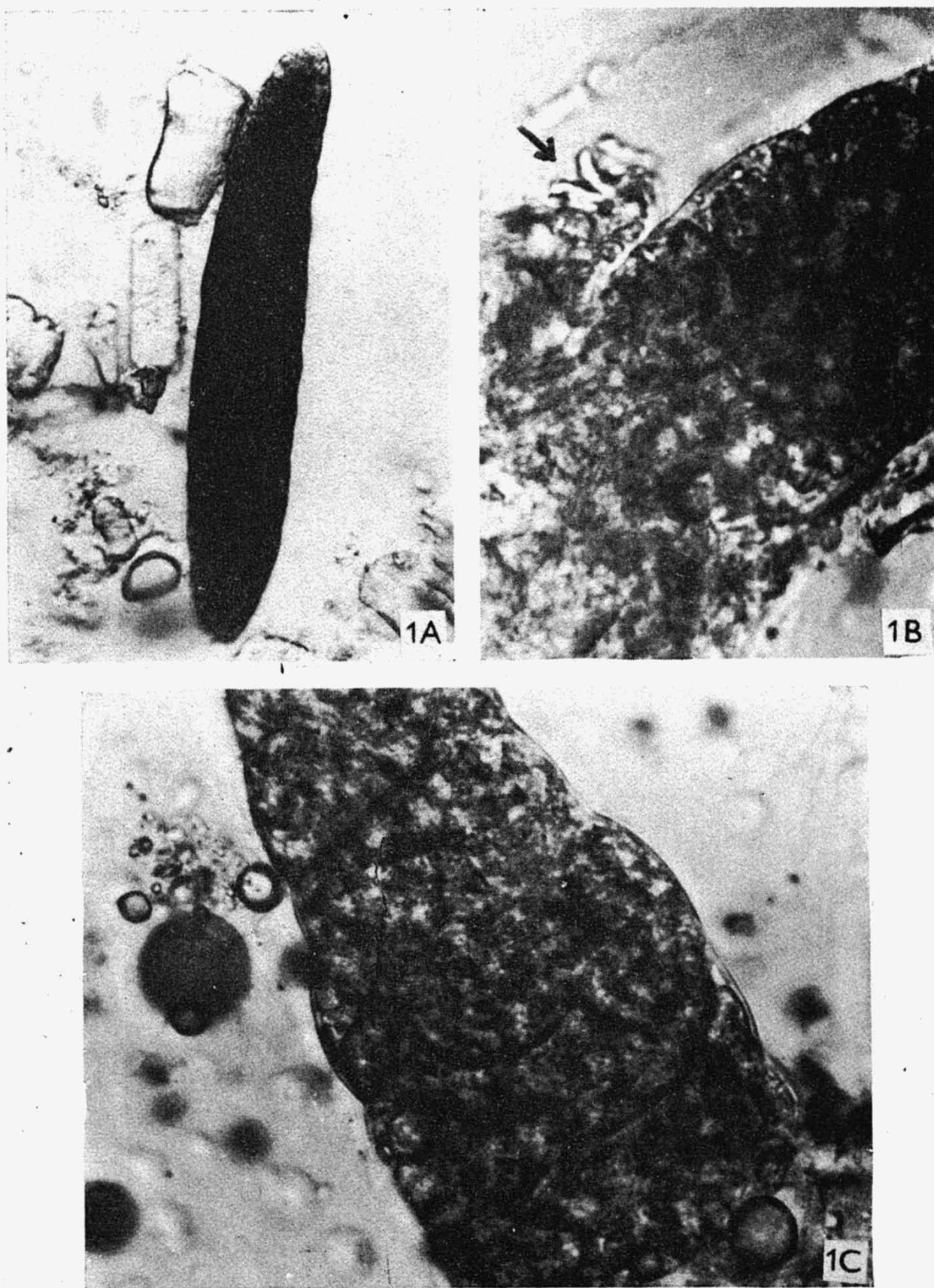


Fig. 1. *Sarcocystis ovicanis* from sheep. A — microscopic cyst in mixed muscles (fragments of muscle fibres — left). ($\times 150$). B — the same cyst after damage of wall. Free cystozoites (arrow). ($\times 900$). C — detail of cyst with thin, smooth wall. ($\times 900$.)