

HUMAN HYDATIDOSIS IN SOUTH BOHEMIA

J. PROKOPIČ, J. ŠTĚRBA and L. NEUBAUER*

Institute of Parasitology, Czechoslovak Academy of Sciences, Prague, and *District Institute of National Health, Strakonice

Abstract. Hydatid cysts were found on histopathological examination of liver from 9 patients at the age of 60–91 years in South Bohemia (Czechoslovakia). These findings suggest that human hydatidosis may occur in old people in Czechoslovakia.

Human hydatidosis induced by the larva of *Echinococcus granulosus* (Goeze, 1782) has been rarely reported in Czechoslovakia. The hydatids have been occasionally found, usually as side findings on post-mortem examinations. As it is documented in the monograph by Jírovec et al. (1977), the number of cases of human hydatidosis has considerably decreased since the beginning of this century. This led even to doubts on the occurrence of *E. granulosus* in Czechoslovakia.

However, systematical studies of dissection material in West and South Bohemia revealed that human hydatidosis is not so rare, particularly in old people (Šlais 1964, Lietava 1970, Štěrbá and Šlais 1972, 1974, Prokopič and Štěrbá 1976, Šlais et al. 1979, Štěrbá and Prokopič 1981, Řehka and Rachunková 1981, Šlais 1981).

Nine cases of human hydatidosis recorded in South Bohemia are described in this paper.

MATERIAL AND METHODS

Since 1973, 8 cases of hydatidosis have been registered at the Department of Pathology and Anatomy, District Institute of National Health, Strakonice Hospital and the last case was recorded at the Department of Pathology, Regional Institute of National Health, České Budějovice Hospital (South Bohemia).

The material was obtained from the liver of 60-91-year-old people (Table 1) including 5 women and 4 men. The liver was fixed in 10 % formol and decalcified with 5 % trichloroacetic acid using a standard paraffin method after Šlais (1964). Both common and special histological methods described by Štěrbá and Šlais (1972, 1974) were used.

RESULTS

The basic anamnestic data are summarized in Table 1. Since all of the hydatid cysts in the livers were side findings, only basic clinical and pathological-anatomical data are given.

Case No. 1. A 80-year-old woman, formerly worker, now pensioner, was admitted to the Department of Surgery with the diagnosis of haemorrhage into digestive tract. At the post-mortem examination, the clinical diagnosis was confirmed and a chronic peptic, deeply penetrating ulcer in pyloric part of stomach was detected. The death was caused by the haemorrhage into the digestive tract and bilateral aspiration pneumonia.

The liver was not increased and weighed 1200 g. A yellow spherical focus measuring 2.5 cm was visible on the convexity of the right lobe. In the section through liver parenchyma there appeared a spherical structure (Plate I, Fig. 1) surrounded by connective tissue and measuring 6 × 5 × 5 cm. Its lobular process reached up to the liver capsule. The cavity was filled with a yellow-white pulpy matter with calcified foci.

Histological picture: cystic cavity encapsulated with connective tissue, with typical double-layered wall. In the vicinity of the connective tissue capsule was a slight chronic inflammatory reaction with single giant multinuclear cells of foreign bodies. The hyaloid membrane was loose at some places and with foci of dystrophic calcification. The cysts contents were disintegrated and the hooks were freely dispersed among the calcium granules.

Conclusion: a fertile, regressively changed hydatid cyst in the liver, encapsulated with connective tissue.

Epidemiological data: the patient kept a dog and cat and had never been in abroad. **Case No. 2.** A 77-year-old man, formerly farm worker, now pensioner. He died at the Department of Internal Medicine with the diagnosis of general arteriosclerosis, status lacunaris, suspect brain vessel damage v. s. strain, bronchopneumonia in the right lobe and extrarenal uremia.

The post-mortem examination revealed arteriosclerotic changes, particularly in brain arteries. Status lacunaris and fresh minute encephalomalacia was observed in the central part of pont and successive and massive terminal embolization into pulmonary artery. Suppurated older haemorrhagic pulmonary infarct was observed in the right lower lobe. An acute insufficiency of right heart was also detected. The liver was enlarged, weighed 2200 g and the capsule was tight. Two cavities, cystic in section, were observed at the convexity of liver under the capsule. The larger one, in the right lobe, measured 20 mm and the smaller, near the margin of the left liver lobe, 15 mm in diameter. Both cavities were arched with several connective tissue bands, among which were clusters of a yellow matter. Other spaces were filled with a transparent, yellow fluid.

The histological picture of both cysts was identical. The cyst wall consisted of a two-layered membrane, outer, very thick zone of newly formed connective tissue bordered by an inflammatory infiltrate and inner, also very thick hyaloid membrane. The cyst contents were accumulated in the centre and consisted of clusters of a large number of scoleces (Plate III, Fig. 1). Characteristic hooks were very numerous, mostly dispersed in the contents (Plate III, Fig. 2). Fragments of double crowns were sometimes preserved (Plate III, Figs. 1, 2). Acute venostasis was observed around the liver parenchyma and strong fibrosis injuring the normal liver architecture was in the areas between the cyst wall and cyst envelope.

Conclusion: encapsulated, regressively changed, fertile hydatid cysts in the liver. The fact that the walls of both cysts were undamaged and that the development of echinococcus and regressive changes were almost identical excludes the possibility of secondary echinococcosis. The duplicity was most probably due to a massive primary infection or a reinfection following immediately after the primary infection.

Epidemiological data: the patient kept a dog and had never been in abroad.

Case No. 3. A 60-year-old man, formerly farmer, now pensioner, died at the Department of Tuberculosis and Respiratory Diseases with the diagnosis of chronic disseminated pulmonary tuberculosis at the phase of disintegration affecting the upper and middle fields of both lungs. A general decrepitude.

The clinical diagnosis was confirmed at post-mortem examination. The liver was not enlarged and weighed 1230 g. A yellow, spherical focus measuring 5 cm in diameter was visible in the convexity of the right lobe. It reached the diameter of 7 cm in the section. The focus was separated from the surrounding parenchyma with a border of connective tissue and was filled with a yellow-white greasy matter.

Histological finding: the fibrous capsule of the cyst was relatively narrow. The inflammatory reaction in the vicinity was very feebly expressed. The hyaloid membrane was loosened and penetrated into the dense contents in form of folded lamellae. In the cyst contents, there were numerous slits made by cholesterol crystals and numerous regressively changed scoleces, the structure of which was well preserved at some places.

Table 1. Survey of anamnestic data from persons with liver cysts caused by *Echinococcus granulosus*

Case no.	Name	Sex	Age	No. of autopsy record	No. of histol. exam.	Death cause	Employment	No. of cysts	Cyst measurement (cm)	Contact with animals
1	P. H.	f	80	Strakonice 537/73	N 331/73	Haemorrhagia into digestive tract	worker	1	6 × 5 × 5	dog cat
2	V. J.	m	77	Strakonice 441/74	N 271/74	Pulmonary embolization, acute failure of right heart	farm worker	2	Ø 2 Ø 1.5	dog
3	K. H.	m	66	Strakonice 451/74	N 282/74	Pulmonary tuberculosis, severe cachexia, bronchopneumonia	farm worker	1	Ø 7	dog
4	K. Č.	f	78	Strakonice 83/77	N 49/77	Haemorrhagia into brain, angiosclerotic encephalopathy, hypertension	weaver	1	Ø 7	dog
5	M. J.	f	81	Strakonice 519/77	N 260/77	Pulmonary embolization, failure of right heart	timber worker	3	Ø 2 Ø 3 Ø 3.7	dog
6	J. D.	m	60	Strakonice 200/79	N 88/79	Suprarenal gland carcinoma, pulmonary bronchiectasia, failure of right heart	worker	1	Ø 5	dog
7	B. M.	f	91	Strakonice 17/81	N 9/81	Angiosclerotic encephalopathy, pulmonary embolization	farm worker	1	4 × 6	dog cat
8	F. Č.	m	78	Strakonice 581/81	N 256/81	Myocardial infarction	postman	1	Ø 1.5	cat
9	M. S.	f	82	Č. Budějovice 430/82	Dr Vo 141/82	Fracture of femur neck, heart failure, terminal embolization	farm worker	3	Ø 2—3	dog cat

Conclusion: a regressively changed, fertile, "areactive" hydatid cyst in the liver, encapsulated with connective tissue.

Epidemiological data: the patient kept a dog and had never been in abroad.

Case No. 4. A 78-year-old woman, formerly weaver, now pensioner. She died at the Department of Neurology with a diagnosis of intracerebral haemorrhagia, ischemic heart disease.

The post-mortem examination revealed a fresh haemorrhagia in the central part of left cerebellum hemisphere perforating into the fourth brain ventricle and subarachnoidal space. The liver was not enlarged, weighed 1440 g and the parenchyma was hyperaemic. A cyst measuring 1.5 cm in diameter and encapsulated with connective tissue (Plate I, Fig. 2) was situated subcapsularly in the convexity of the left liver lobe. The cyst cavity was filled with a calcified, non-homogeneous, granular, yellow-white matter (Plate I, Fig. 2).

Histological picture: strongly regressively changed, dystrophically calcified, fertile hydatid cyst. The fibrous envelope consisted of a thick layer of newly formed, completely hyalinized connective tissue. Outside this zone was a conspicuous chronic inflammatory infiltrate. The hyaloid membrane was very damaged at many places, but its lamellar structure was well preserved. The cyst contents consisted of a non-homogeneous matter with numerous slits made by cholesterol crystals and with single parasitic hooks.

Epidemiological data: the patient kept a dog and had never been in abroad.

Case No. 5. A 81-year-old woman, formerly timber worker, now pensioner. Three weeks before the death she was operated on senile cataract. After the operation, a thrombosis occurred in both lower limbs and the patient died of pulmonary embolism.

The post-mortem examination confirmed the clinical diagnosis. An extensive massive embolism in main strains and branches of pulmonary artery led to an acute failure of the right heart. Three white foci were found in the liver (weighing 1600 g) under the capsule of the right liver lobe. In the section there appeared three spherical and partly dystrophically calcified hydatid cysts of different size (measuring 2, 3, and 7 cm in diameter). They contained characteristically undulated typical hyaloid membranes.

Histological picture: in all three cases there were hydatid cysts encapsulated with connective tissue, of common histological structure and with a very thick hyaloid membrane and numerous acidoresistant hooks, characteristically staining blue with Giemsa stain. The low degree of regressive changes and dystrophic calcification indicates that the process was rather fresh.

Conclusion: fertile, slightly regressively changed hydatid cyst in the liver, encapsulated with connective tissue.

Epidemiological data: the patient kept a dog and had never been in abroad.

Case No. 6. A 60-year-old worker (formerly farm worker) was repeatedly hospitalized at the Department of Tuberculosis and Respiratory Diseases with the diagnosis of obstruction bronchopulmonary disease and chronic failure of right heart.

On post-mortem examination, the clinical diagnosis was confirmed and extensive bronchiectasias and chronic heart failures were detected. A non-generalized carcinoma of suprarenal gland cortex was also observed. The liver was not enlarged, weighed 1470 g, and a spherical cyst was visible under the capsule of the right liver lobe convexity. In the section through parenchyma it measured 5 cm in diameter and single undulated and wrinkled hyaloid membranes of echinococcus were situated in its yellow gelatinous contents (Plate I, Fig. 3).

Histological picture: a cyst encapsulated with connective tissue and filled with granular serose contents with dystrophic calcifications, characteristic lamellar arrangement of hyaloid membrane stained by Gomori's method and hooks stained by Giemsa.

Conclusion: a moderately regressively changed, fertile hydatid cyst in the liver.

Epidemiological data: the patient kept a dog and had never been in abroad.

Case No. 7. A 91-year-old woman, formerly farm worker, now pensioner, hospitalized with symptoms of ileus and senile dementia. After infusions with cardiotonics and temporary improvement the patient suddenly died on the second day.

The post-mortem examination revealed a general sclerosis of 3rd stage, sclerotic encephalopathy and massive pulmonary embolization and thrombosis of arteria mesenterica as a cause of the ileus. The liver weighing 1220 g contained an oval hydatid cyst (measuring 4 × 6 cm) in the right lobe (Plate I, Fig. 4).

Histological picture: the same as in the previous observation.

Conclusion: a regressively changed fertile hydatid cyst in the liver.

Case No. 8. A 78-year-old man, formerly postman, now pensioner, was hospitalized with acute myocardial infarction, of which he died.

The post-mortem examination confirmed the myocardial infarction and revealed a thrombosis of both lower limbs and massive pulmonary embolization. The liver weighing 1680 g contained a partly calcified oval cyst measuring 1.5 cm in diameter and situated in the lower part of the right liver lobe. Markedly undulated hyaloid membranes were found in the gelatinous and partly calcified contents of the cyst (Plate II, Fig. 3). **Histological picture:** a cyst encapsulated with connective tissue and filled with hyaloid membranes and characteristic lamellar arrangement staining well with van Gieson's stain (Plate IV, Fig. 1), Gomori's impregnation method and PAS (Plate IV, Fig. 2) illustrating the alternation of acid and neutral mucopolysaccharides in the hyaloid membrane. In all described hydatid cysts pigment was demonstrated at places of the original small germinative membrane on the inner side of cuticular membrane. Scolex hooks staining blue with Giemsa and remnants of disintegrating scoleces were dispersed in the granular cyst contents. There were numerous slits made by cholesterol crystals (Plate IV, Fig. 1).

Conclusion: a slightly regressively changed, fertile hydatid cyst in the liver.

Epidemiological data: the patient kept a cat, never had a dog and never was in abroad. As a postman he could get into contact with contaminated environment or with a dog.

Case No. 9. A 82-year-old woman fell down and broke the neck of the left femur. In spite of the intensive therapy she died with symptoms of heart failure.

The post-mortem examination demonstrated that the cause of the death was the heart failure at a general arteriosclerosis. Moreover, fibrosis, a scar after myocardial infarction in posterior wall of left ventricle, enlargement of the whole heart, and widening and inertia of the right ventricle on terminal embolization into pulmonary artery were observed. The liver weighed 1210 g and its surface was slightly convex at three places. Three cysts measuring 2—3 cm in diameter were found there under the capsule in parenchyma. The cysts were filled with grey and brown matter with hydatid membranes (Plate II, Figs. 1, 2).

Histological picture: the cysts contained numerous slits made by cholesterol crystals and numerous regressively changed scoleces. Single giant multinuclear cells of foreign bodies were in the vicinity of cholesterol crystals. The outer wall of cysts was formed from a markedly hyalinized connective tissue (Plate IV, Fig. 3), to which adhered characteristically arranged hyaloid membranes closing the exudate with regressively changed scoleces (Plate IV, Figs. 3, 4a) and masses of typically staining hooks (Plate IV, Figs. 4a, b).

Conclusion: fertile, slightly progressively changed hydatid cysts in the liver.

Epidemiological data: the patient kept a dog and cats and had never been in abroad.

DISCUSSION

The man is blind alley in the life cycle of *Echinococcus granulosus*, but still the larva can develop in various human organs. According to Cameron (1958), more than 50 % of hydatid cysts are localized in the liver. The author states that in human pathology, hydatidosis is usually studied in adult patients at the age of 20—40 years, whereas it occurs much more frequently in children and young people, though in 90 % of cases no

complications develop. Hydatid cysts occurring in this age category are usually smaller (like hazel nut), sterile and very frequently they are encapsuled and calcified.

Such cases were most often encountered in our patients, as it was reported by Prokopič and Štěrba (1976). Not a single hydatid cyst among the 39 cases recorded (30 from West Bohemia and 9 from South Bohemia) exceeded the size of a walnut and often the cysts were at various degree of regression and calcification. Since the developed hydatid cysts occurred mostly in very old people, it may be supposed that it is due to a decreased resistance of the organism physiologically weakened by other diseases and old age, so that the parasite can get over the immunological barrier and fully develop.

Píša (1937) reported that human hydatidosis occurred much more frequently in our country in earlier times. The hydatid cysts reached a great size and clinical symptoms often resulted in the death. The author recorded a finding of a hydatid cyst reaching the size of a child head (17 cm) in a 54-year-old man. Tomek et al. (1963) found a hydatid cyst in the myocardium of a 48-year-old man. Lietava (1970) recorded a hydatid cyst in the liver of a 32-year-old woman. The hydatid cysts found by us were localized in the liver of patients at the age of 60—91 years.

Also *Linguatula serrata* Frölich, 1789 occurs more frequently in older people, at the age of 60—80 years. Man can become infected with this parasite through the dog, like in case of *E. granulosus*. Most probably the old people have a more intimate contact with domestic animals, particularly dogs and cats, and with regard to their age, a lower hygienic level and immunological resistance can be supposed. These are probably the main factors of the occurrence of some helminthoses in old people.

Acknowledgements. The authors thank MUDr. K. Štěrba, Head of the Department of Pathology of the District Institute of National Health in Strakonice and MUDr. V. Holý, Head of the Department of Pathology of the Regional Institute of National Health in České Budějovice for providing the material and for valuable advice in processing it.

ГИДАТИДОЗ ЧЕЛОВЕКА В ЮЖНОЙ ЧЕХИИ

Я. Прокопич, Й. Штерба и Л. Нойбауер

Резюме. При гистопатологическом обследовании обнаружены гидатидные кисты в печени 9 пациентов в возрасте 60—91 лет в Южной Чехии (Чехословакия). Эти находки свидетельствуют о том, что гидатидоз человека встречается у старых людей в Чехословакии.

REFERENCES

- CAMERON T. W. M., Parasites of animals and human disease. Ann. New York Acad. Sci. 3: 564—573, 1958.
- JÍROVEC O., et al., Parasitologie pro lékaře. (Parasitology for physicians.) Avicenum, Praha, 798 pp., 1977. (In Czech.)
- LIETAVA P., A case of human echinococcosis confirmed in the laboratory. Veterinářství 20: 563—565, 1970. (In Slovak.)
- PÍŠA V., Difficult differential diagnoses of echinococcus in liver accompanied with a subphrenic abscess. Prakt. lékař 22: 1—6, 1937. (In Czech.)
- PROKOPIČ J., ŠTĚRBA J., About some of little known zoonoses of man in Czechoslovakia. Third Internat. symposium of the Helminthological Institute SAV Košice 12—15 October 1976 in High Tatra Mts., Czechoslovakia. Theses and reports, Košice 1976.
- ŘEHKA V., RACHUNKOVÁ A., Menschliche Bandwurmfunde aus Gottwaldov. Angew. Parasitol. 22: 13—20, 1981.
- ŠLAIS J., Histologischer Nachweis der Reste von Echinokokkus-Zysten. Čs. Parasitol. 11: 339—341, 1964.
- , Capsulation of the hydatid cyst of the tapeworm *Echinococcus granulosus* in the liver and in the lungs. Plzeň. Lék. Sborn. 49: 43—50, 1981. (In Czech.)
- , MÁDLE A., VANKA K., JELÍNEK F., ČERNÍK V., Alveolar hydatidosis (echinococcosis) diagnosed by punctional liver biopsy. Čas. Lék. čes. 118: 472—475, 1979. (In Czech.)
- ŠTĚRBA J., PROKOPIČ J., Some zoonoses

diagnosed in the necroptic material. Conference of pathologists of the South-Bohemia Region, 18 November 1981, České Budějovice. (In Czech.)

—, ŠLAIS J., On the nodular lesions of the liver. Plzeň. Lék. Sborn. 37: 75—78, 1972. (In Czech.)

Received 16 August 1982.

Translated by: M. Dašková

—, —, Beitrag zur Diagnose der in der Leber des Menschen vorkommenden knotenförmigen Gebilde. Zbl. allg. Path. 118: 124—131, 1974.

TOMEK J., ŘEHKA V., ROZHONOVÁ J., A cyst of echinococcus in myocardium. Čs. parasitol. 10: 283—284, 1963. (In Czech.)

J. P., Parasitologický ústav ČSAV, Flemingovo n. 2, 166 32 Praha 6, ČSSR

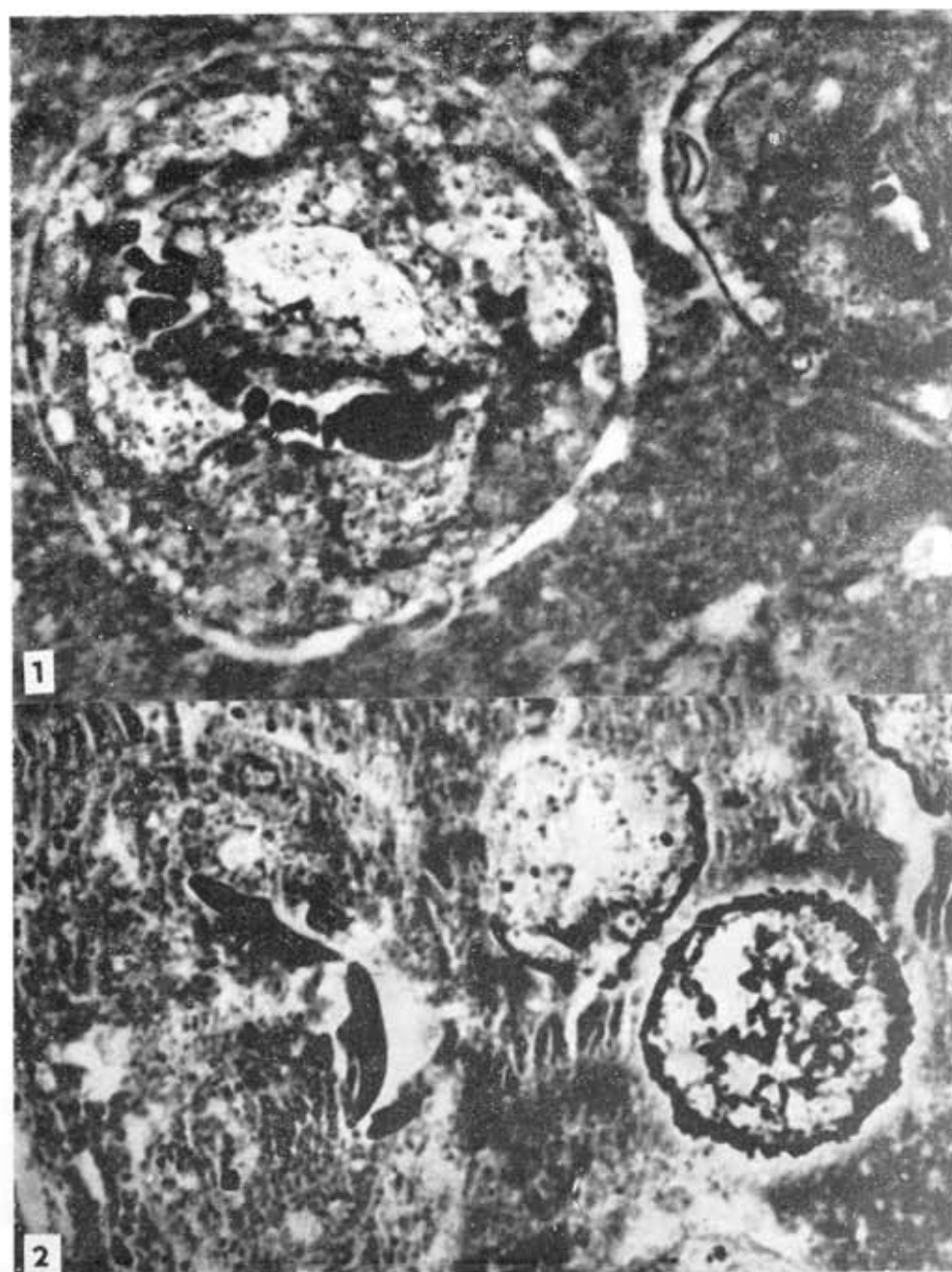

Fig. 1. Detail of scoleces from fertile hydatid cyst. Polarization photomicrograph ($\times 1000$). Fig. 2. Remnants of scoleces and released characteristic hooks of echinococcus. Polarization photomicrograph ($\times 1000$).




Fig. 1. Lamellar arrangement of hyaloid membrane and cavities made by cholesterol crystals. Van Gieson ($\times 280$). Fig. 2. Marked alternation of acid and neutral mucopolysaccharides in hyaloid membrane. PAS ($\times 450$). Fig. 3. Markedly hyalinized connective tissue (at the bottom) adhering to hyaloid membrane enveloping the exudate. Van Gieson ($\times 100$). Fig. 4a. Detail from Fig. 3. Exudate with regressively changed scoleces and masses of typically staining hooks. Giemsa ($\times 400$). Fig. 4b. Detail of characteristic hook of echinococcus. Giemsa ($\times 800$).

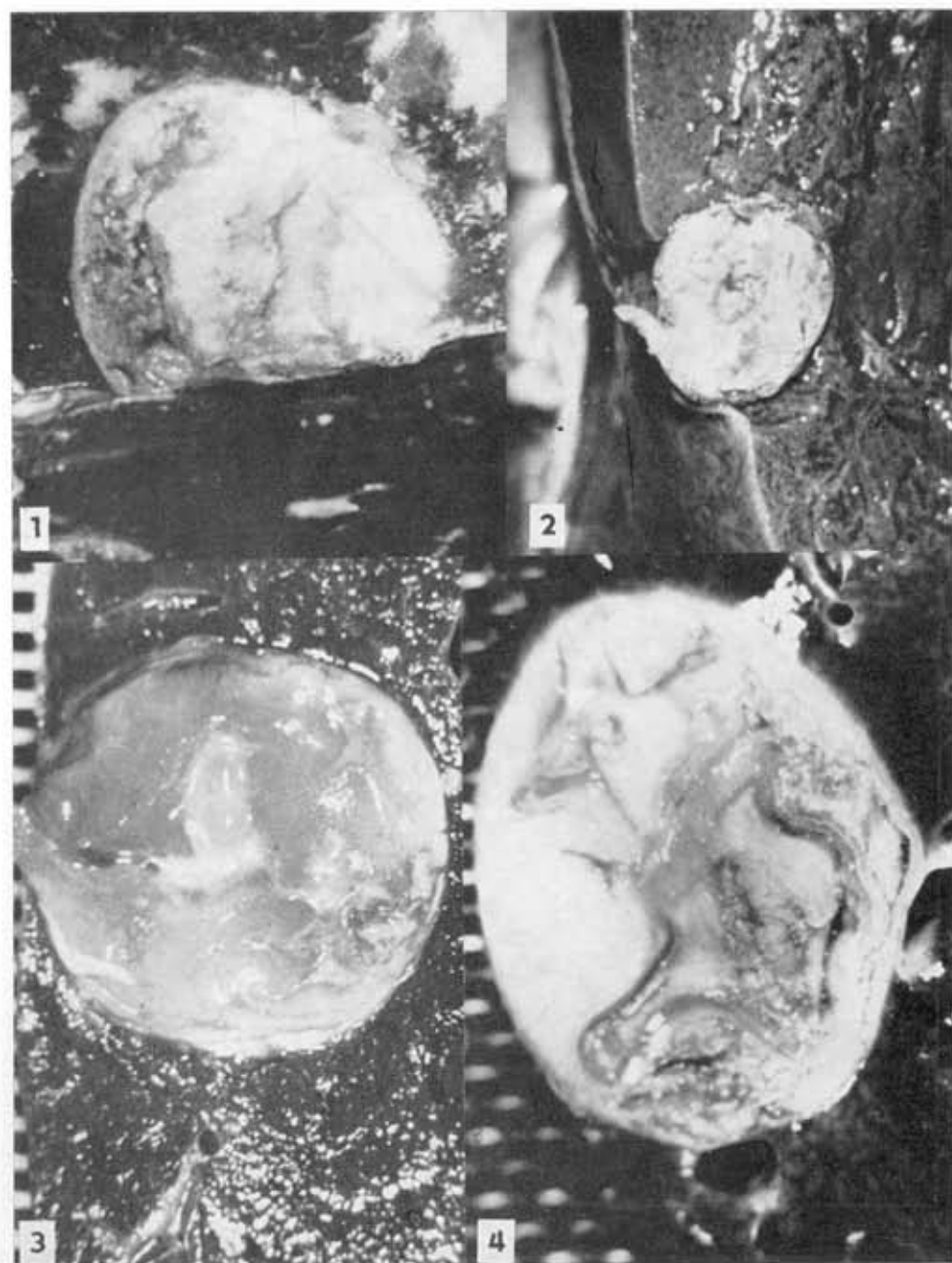
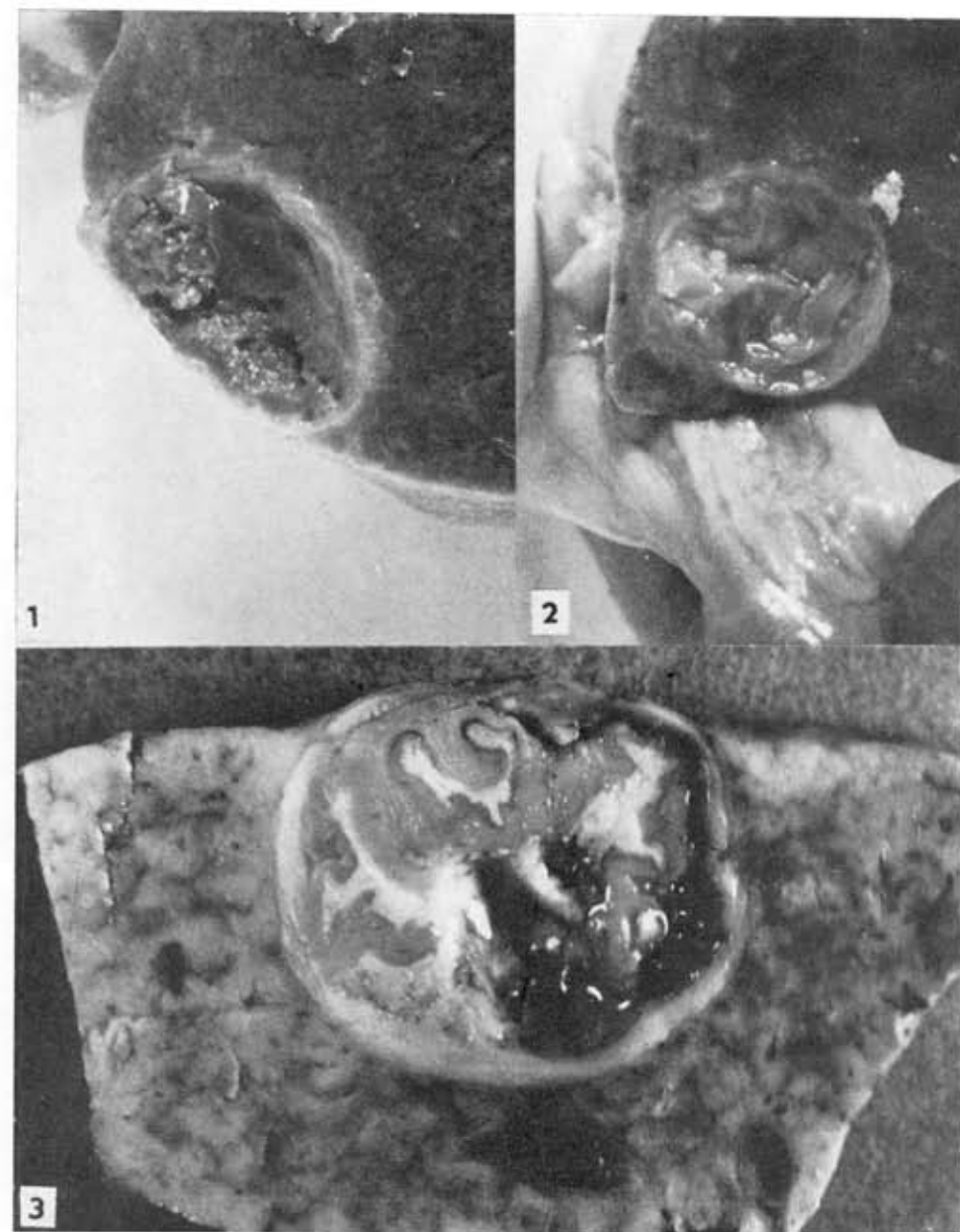


Fig. 1. Section through liver parenchyma with hydatid cyst. **Fig. 2.** Hydatid cyst situated subcapsularly, filled with granular yellow-white matter. **Fig. 3.** Hydatid cyst. Single undulated and wrinkled hyaloid membranes visible in the gelatinous contents. **Fig. 4.** Oval hydatid cyst with conspicuous hyaloid membranes.



Figs. 1. 2. Two of three hydatid cysts in the liver of 82-year-old woman. Cysts are filled with grey and brown matter, with hyaloid membranes. **Fig. 3.** Hydatid cysts with conspicuous hyaloid membranes.